

# Lateral Cephalometric Analysis

Dr Maryam Karandish

Orthodontic Department, Dental School, Shiraz University of Medical  
Sciences, Shiraz, Iran

# Overview

- Definition
  - Historical overview
  - Importance
  - Definition
  - Uses
  - Technique
- Cephalometric evaluation
  - Method of analysis
  - Tracing
  - Landmark and lines
  - Analysis
    - Dental
    - Skeletal
    - Soft tissue

# 1. Definition

## 1.1: Historical view

- Clinically by the overall profile view of the patient. Barnett 1975
- Palpation of anterior surfaces of the basal part of the jaw. Mills 1987
- Better assessment with lateral skull radiograph. Pacini 1922 – Cephalometrics
- Broadbent (USA), Hofrath (Germany) 1934 –Standardization and Popularization

## 1.2: Importance

- Hard tissue
- Dental tissue
- Soft tissue

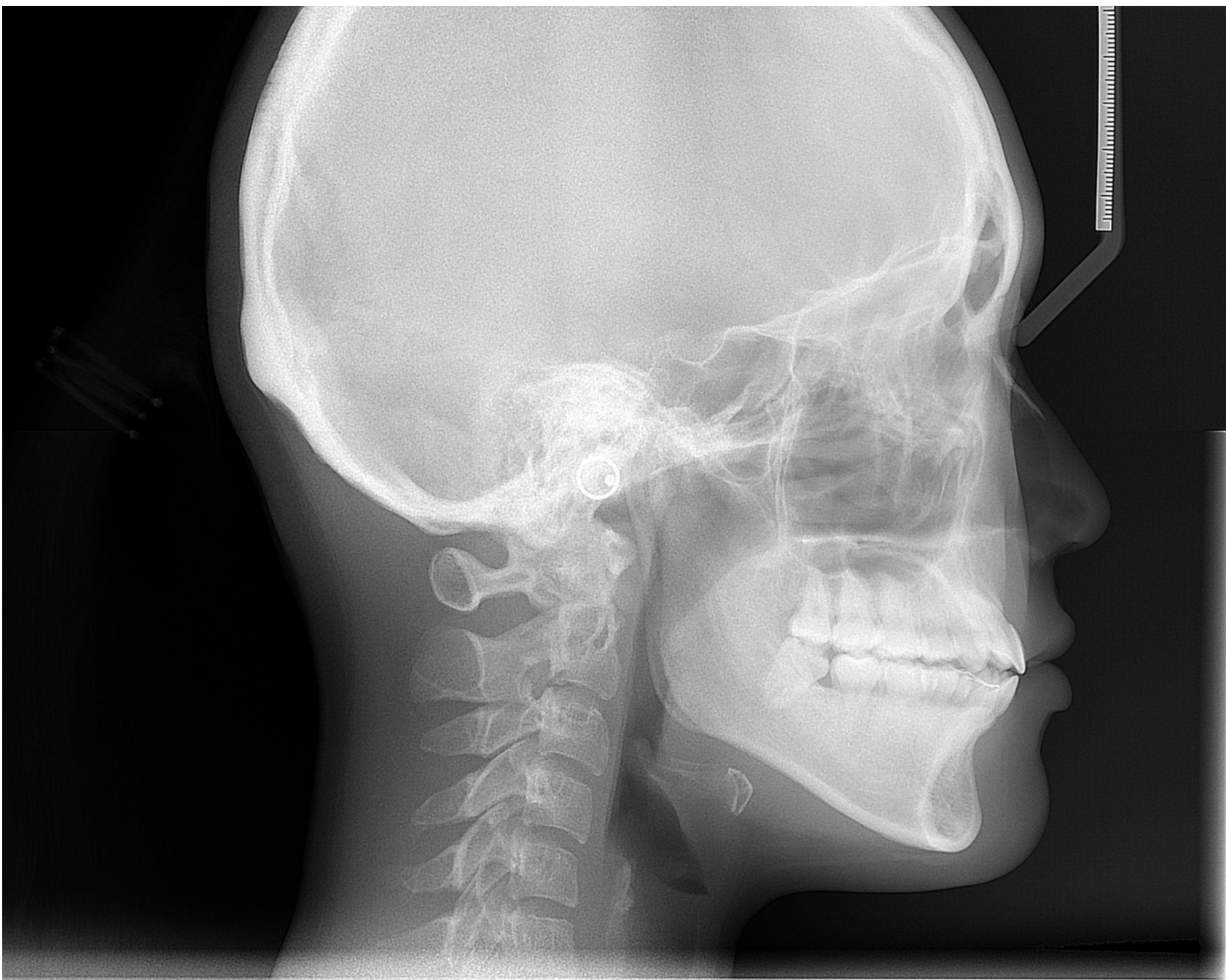
Many of the difficulties experienced in the treatment can be attributed directly to the extent of the excessive disharmony of the skeletal pattern.

## 1.2: Importance (cont'd)

- Simply calling a dimension 'large' or 'small' or 'good' or 'bad' does not mean the same to everyone. In order to be critical or descriptive it is more useful to express dimensions in terms of angles or linear measurements.

BUT

- Cephalometrics is not an exact science



## 1.3: Definition

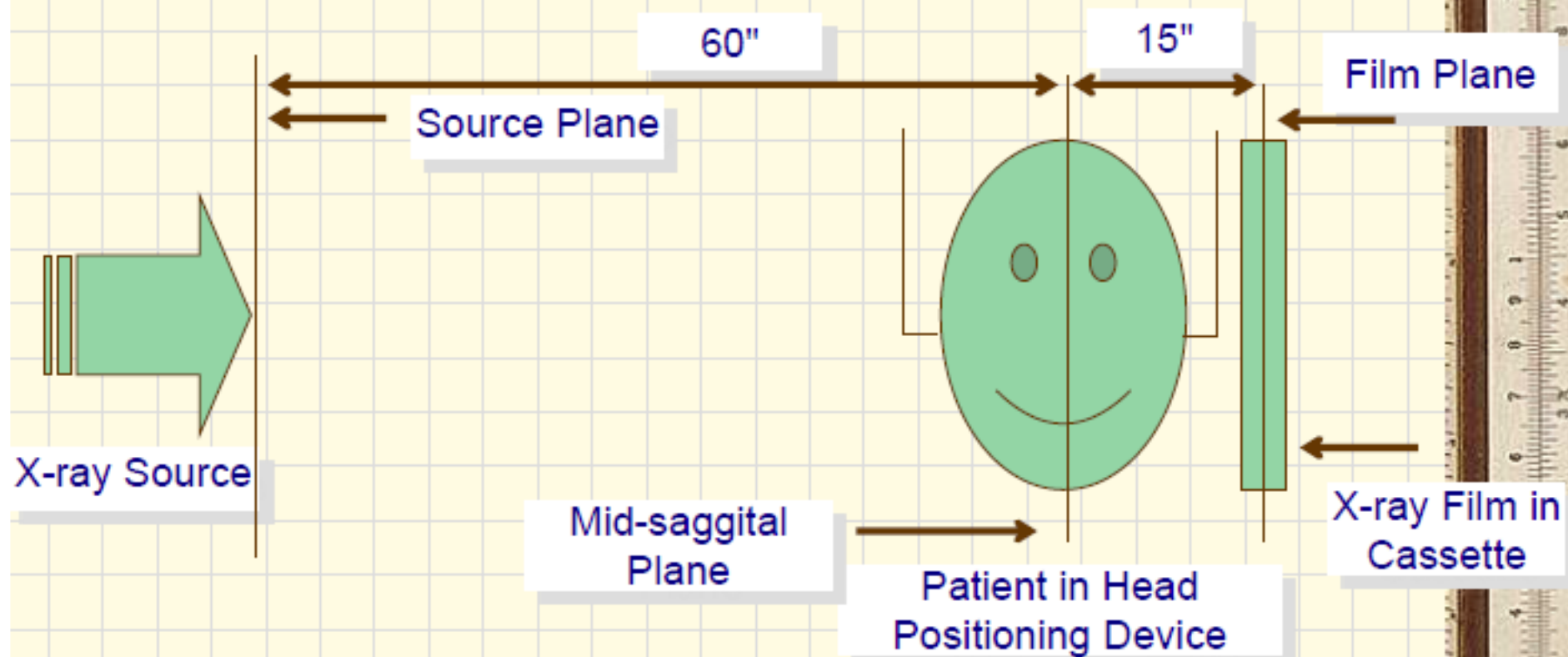
- Cephalometric radiography is a standardized and reproducible form of skull radiography used extensively in orthodontics
- Standardization was essential for the development of cephalometry



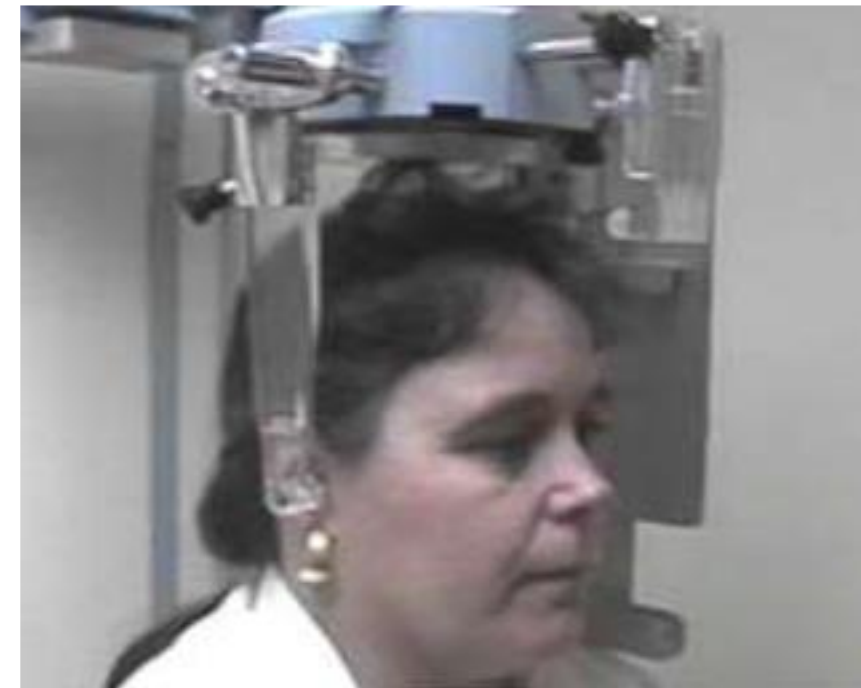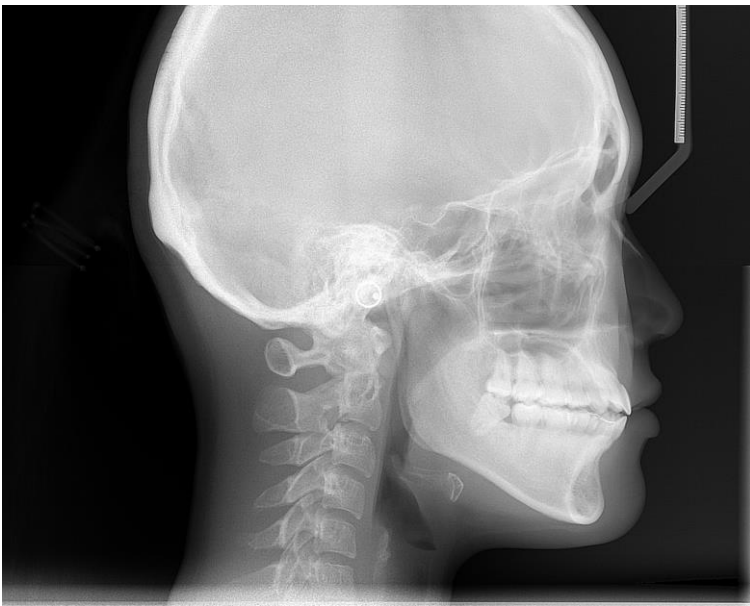## 1.4: Uses

- Diagnosis
- Treatment planning
- Monitoring treatment progress
- Appraisal of treatment results
- Growth studies

# Cephalostat



## 1.5: Technique, Cephalostat



## 1.5: Technique, Natural Head Posture (NHP)

- True vertical line
- Horizon, mirror, orthoposition (1 step forward)
- chain

## 2. Cephalometric evaluation

- Find out skeletal classification
  - Anteroposterior
  - vertical
- Find out angulation of incisors
- Consider soft tissue
  - facial profile
  - airway considerations

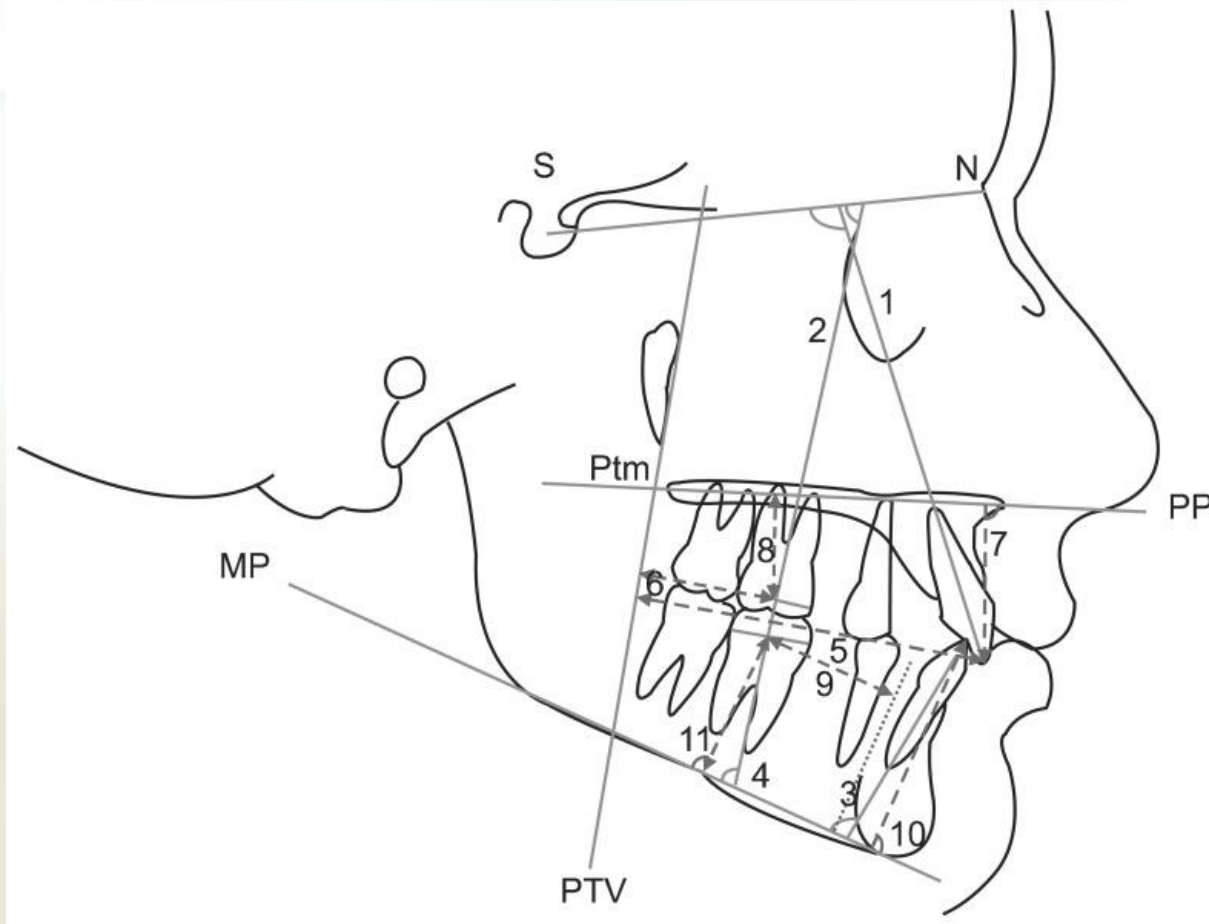
## 2. Cephalometric evaluation (cont'd)

- Identification of anatomic landmarks
- Landmarks: stable reference structures maxillary and mandibular skeletal and dental
- Graphically relating the dento-facial elements to these reference structures
- Angular and or linear measurements

## 2.1: Methods of cephalometric analysis

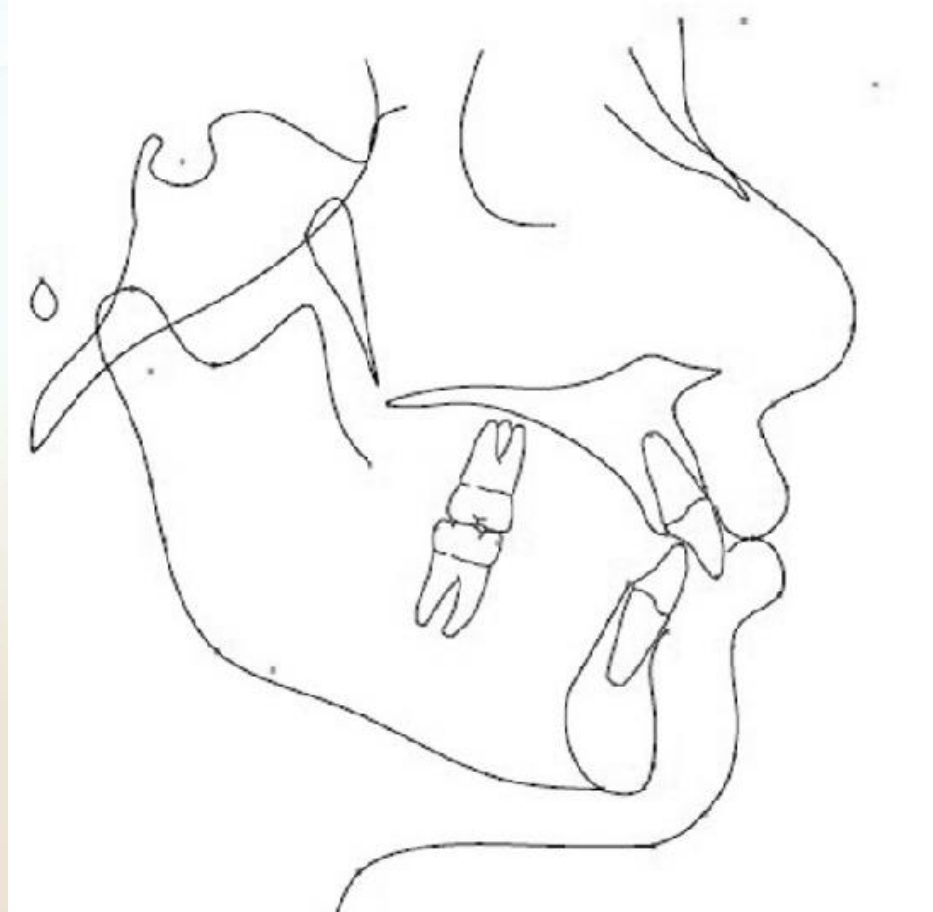
- Two basic approaches:
  - Metric approach - use of selected linear and angular measures
  - Graphic approach - “overlay” of individual’s tracing on a reference template and visual inspection of degree of variation

## 2.1.1: Metric method





## 2.1.2: Graphic method

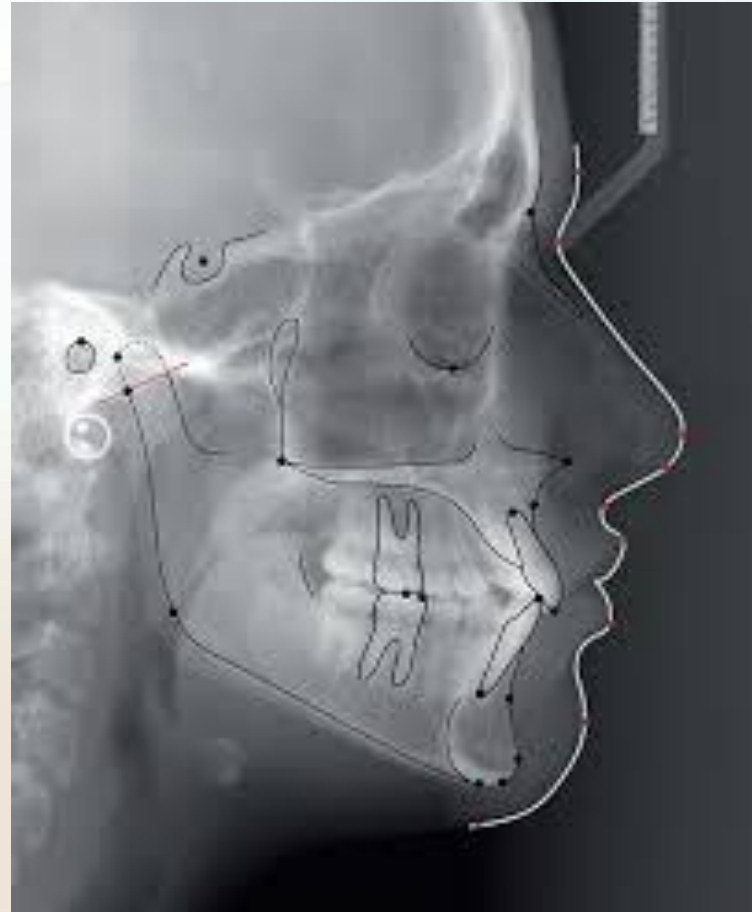


# GOALS OF CEPHALOMETRIC ANALYSIS

Evaluating relationships, both horizontal and vertical of 5 major functional components of the face:

- The cranial base
- The maxilla
- The mandible
- The maxillary dento-alveolus
- The mandibular dento-alveolus

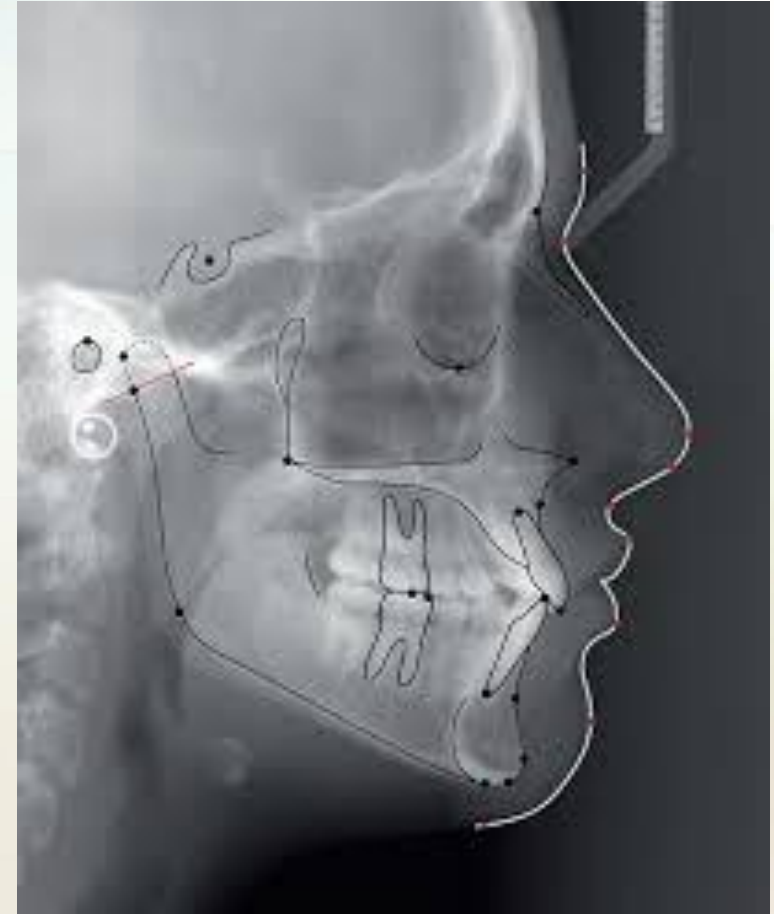
# LATERAL CEPHALOMETRIC TRACING



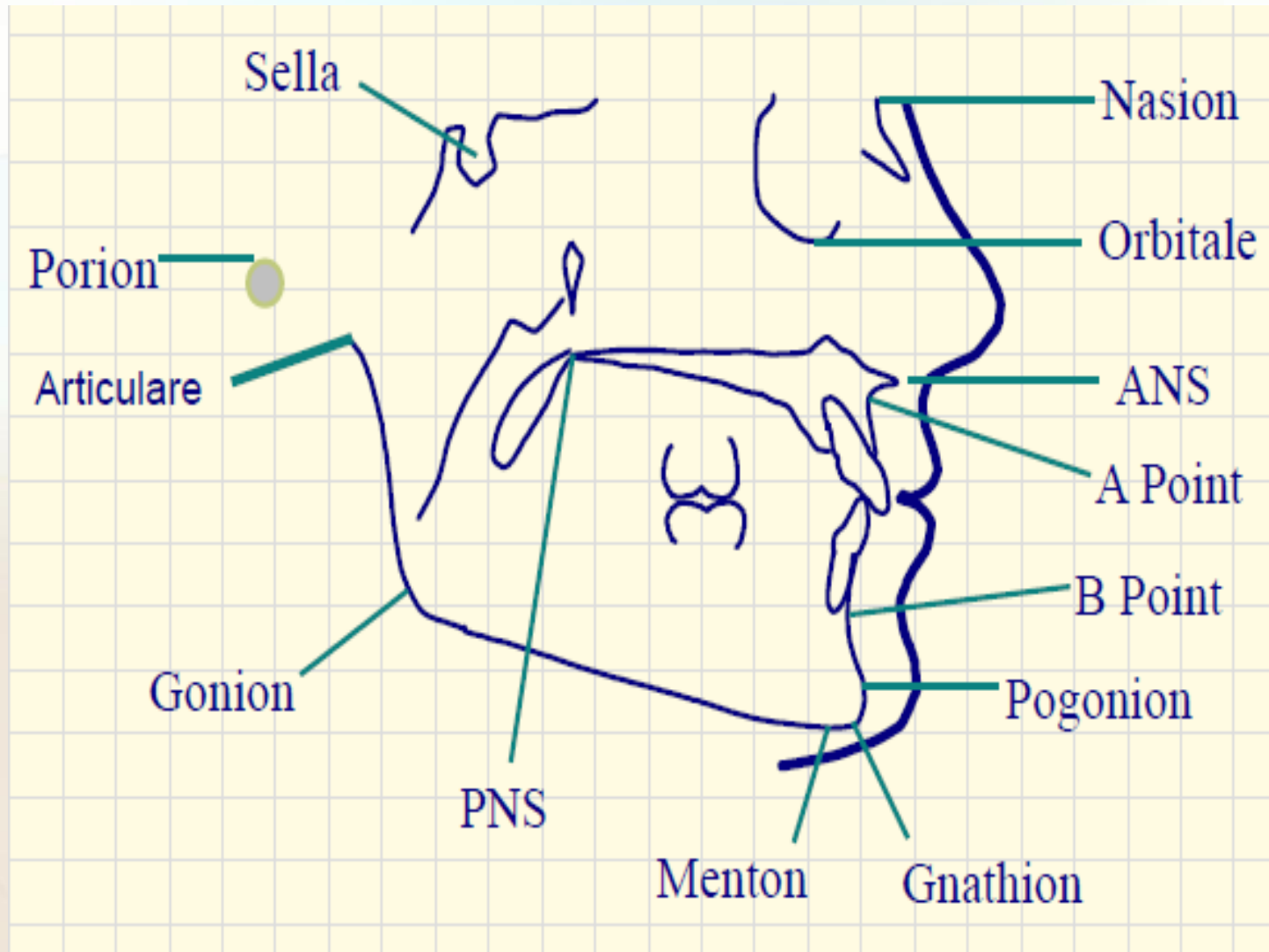
# STEPS OF TRACING

Draw:

- soft tissue outline
- Cranial base
- Midface structures
- Maxillary dentition
- Mandibular structures
- Mandibular dentition

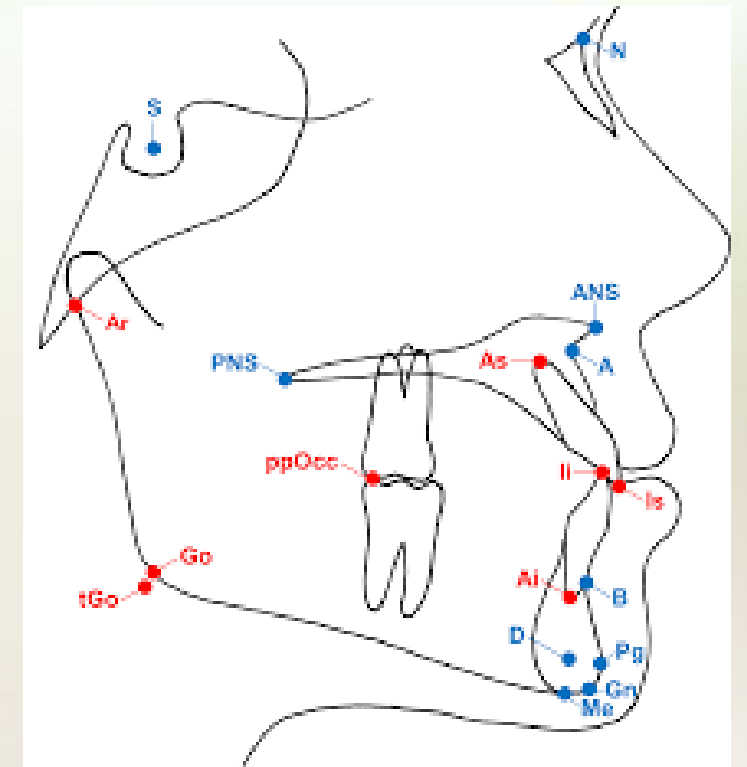


# Cephalometric Landmarks



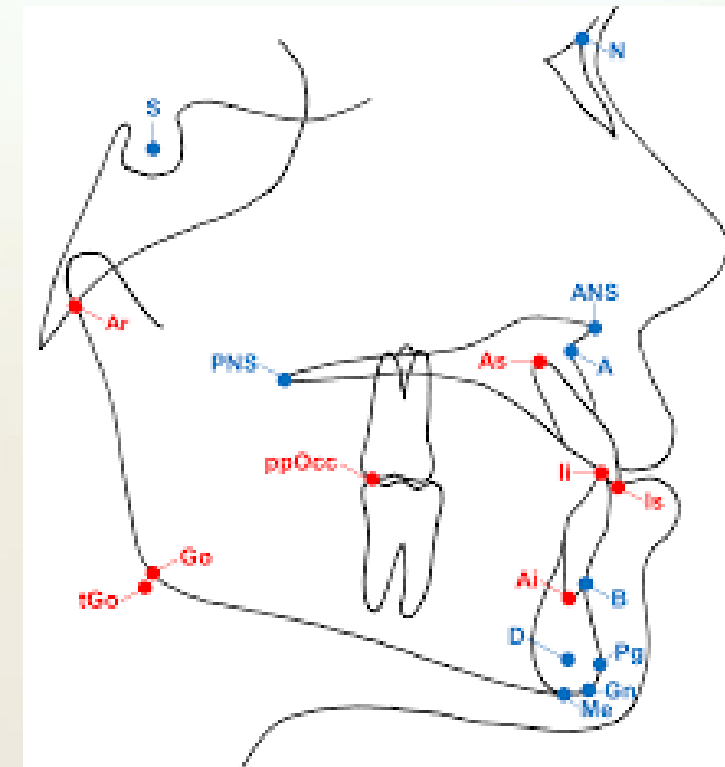
# Cephalometric Landmarks (cont'd)

- **Sella**: Centre of sella turcica
- **Nasion**: Most anterior point on frontonasal suture
- **Orbitale**: Lowest point on infraorbital margin
- **ANS**: Tip of ant nasal spine
- **PNS**: Tip post nasal spine



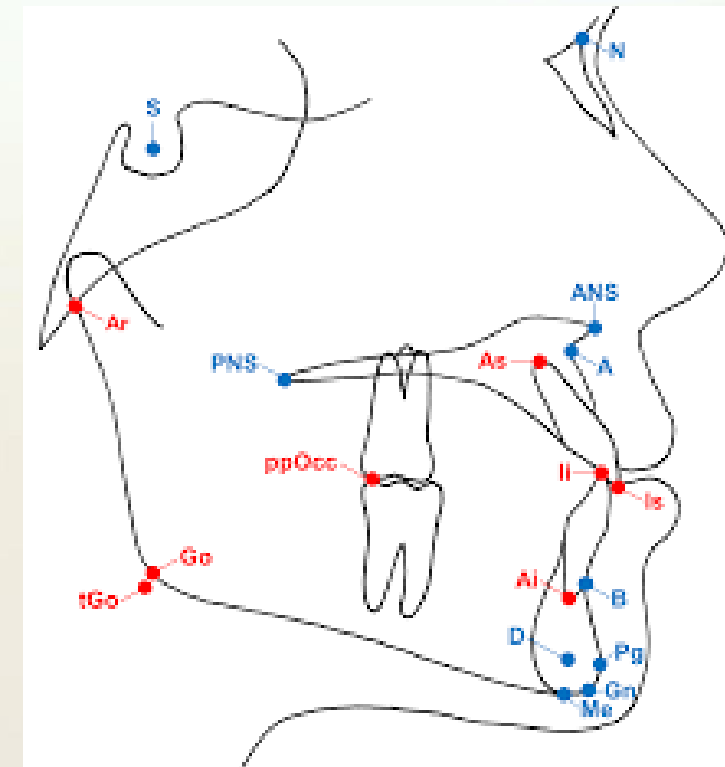
# Cephalometric Landmarks (cont'd)

- **Point A:** Deepest midline point b/w ANS and prosthion
- **Point B:** Deepest point in the bony outline b/w infradentale and pogonion
- **Pogonion:** Most ant point on bony chin
- **Gnathion:** Most anterior and inferior on bony chin
- **Menton:** Lowest point on the bony outline of the md symphysis



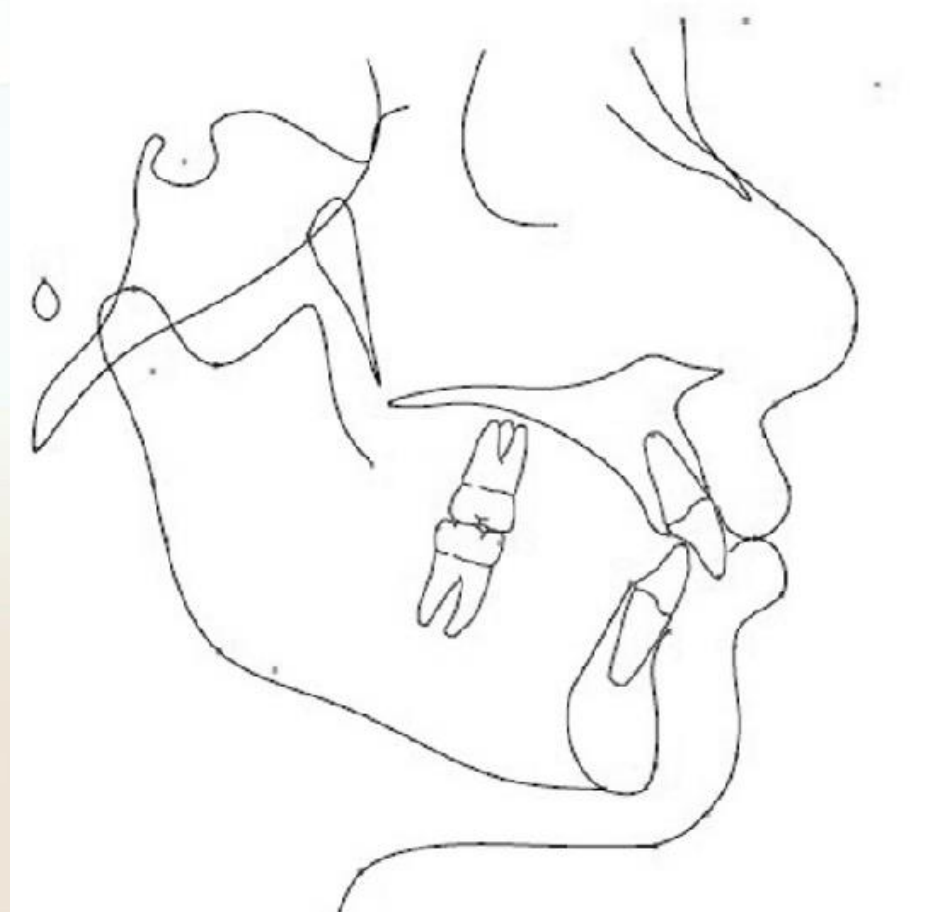
# Cephalometric Landmarks (cont'd)

- **Gonion**: Most lateral external point at the junction of horizontal and ascending rami of the mandible
- **Articulare**: Intersection post border of ramus and temporal bone
- **Porion**: Upper most point on the EAM

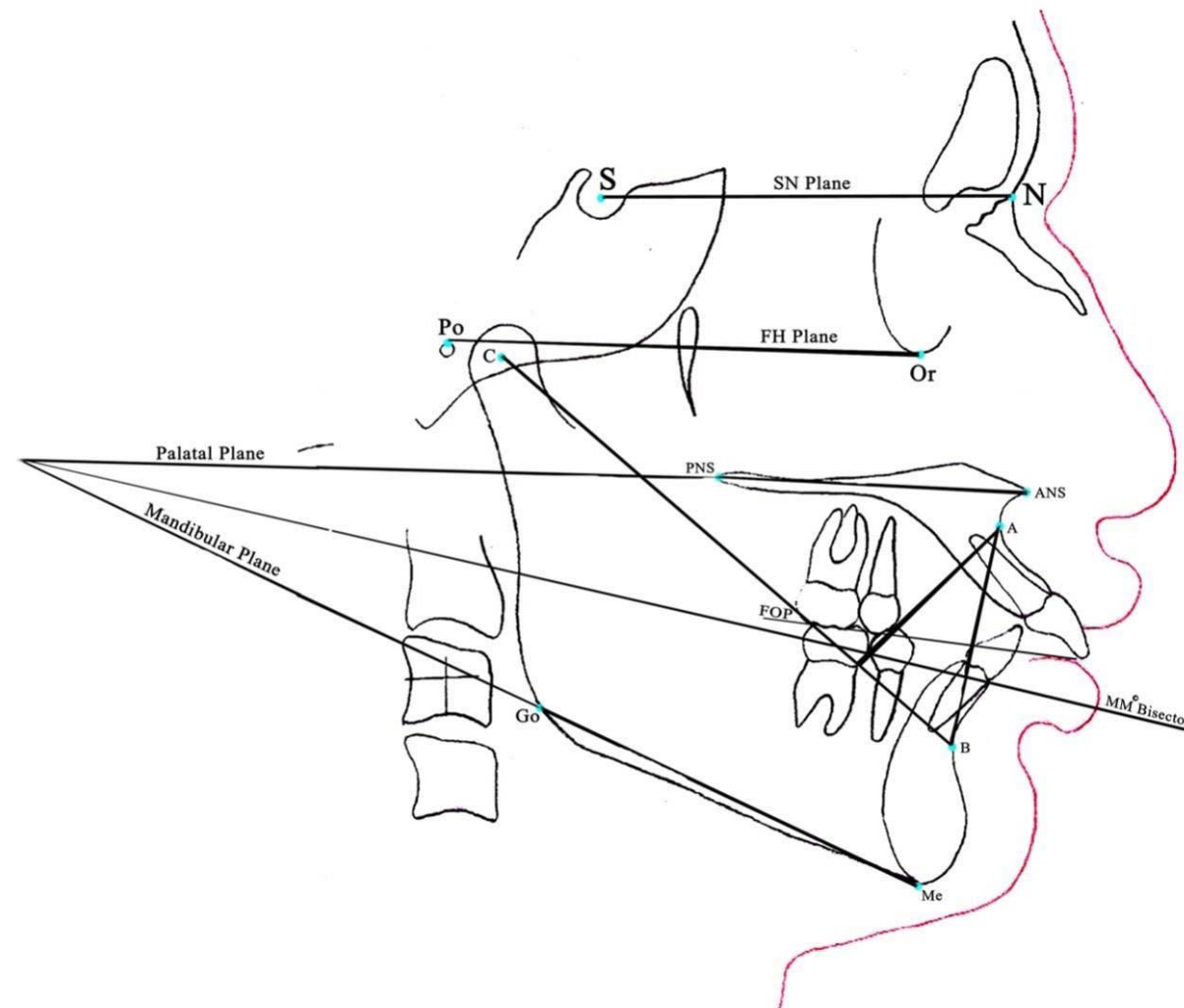




# Structures to be traced



# Planes



# Cephalometric Analyses

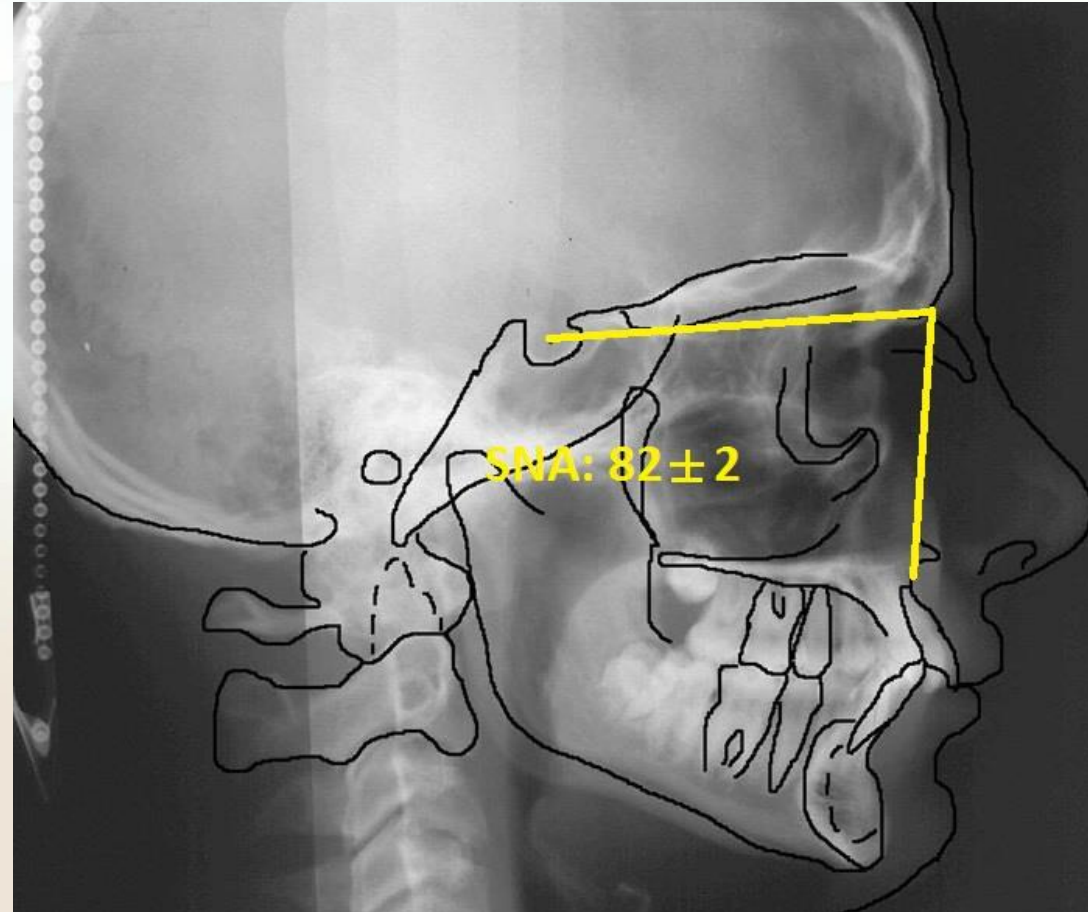
- Down's
- Steiner's
- Tweed's
- McNamara's
- Wits
- Rickett's

# Approach to analysis

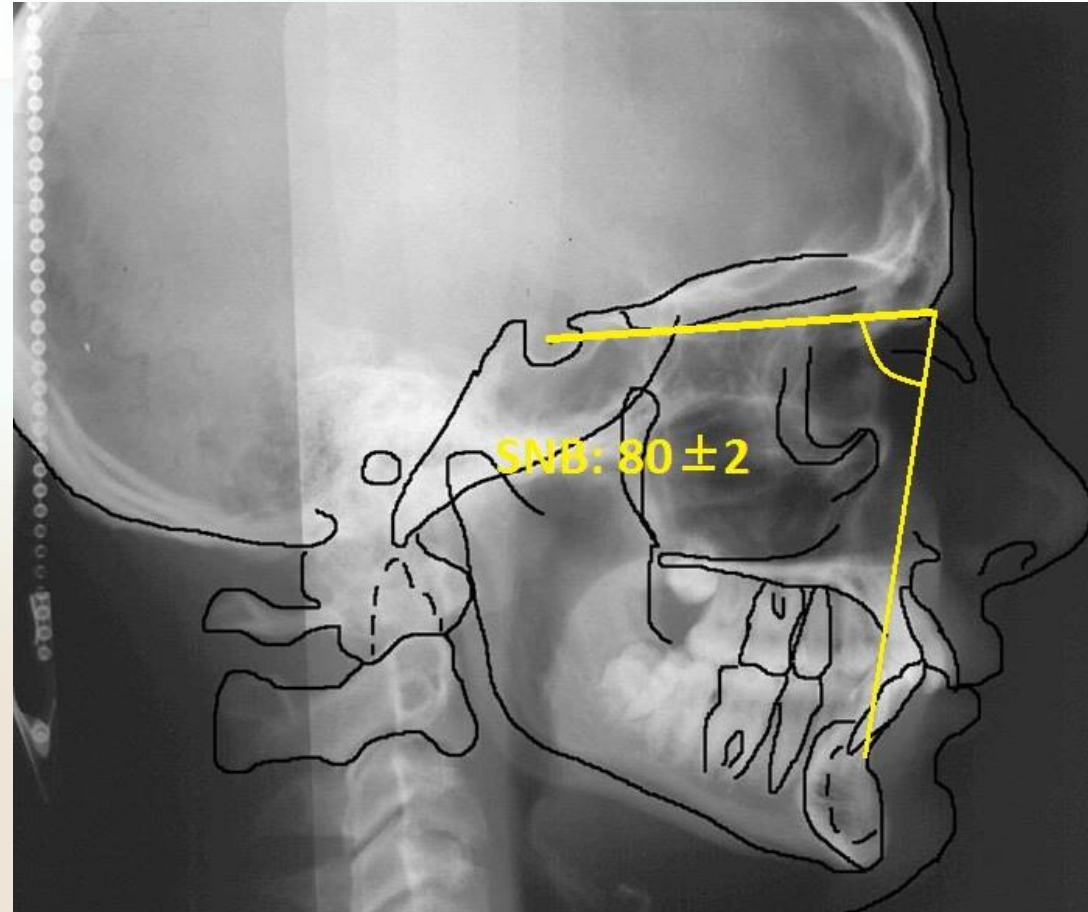
- Sagittal Analysis
- Vertical Analysis
- Dental Analysis
- Soft Tissue Analysis

# Sagittal analysis

# Sagittal analysis – skeletal horizontal maxilla

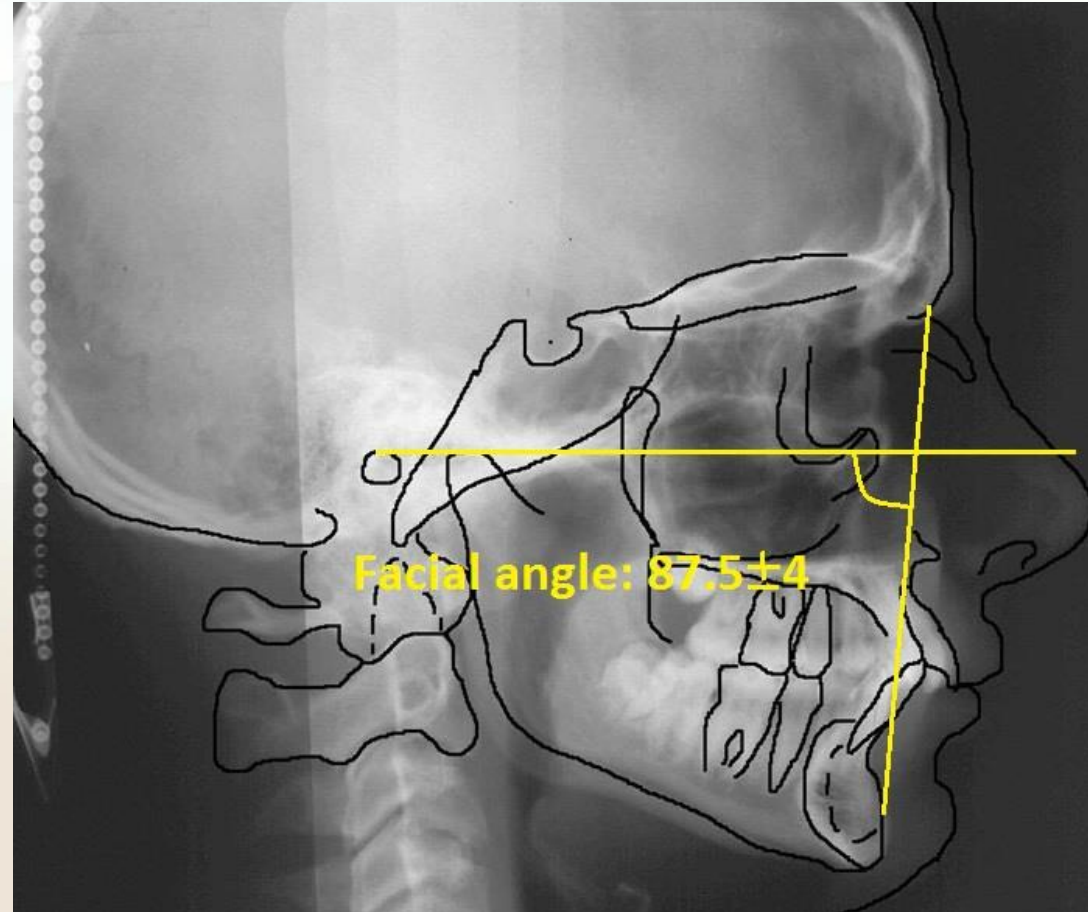


# Sagittal analysis skeletal horizontal mandible



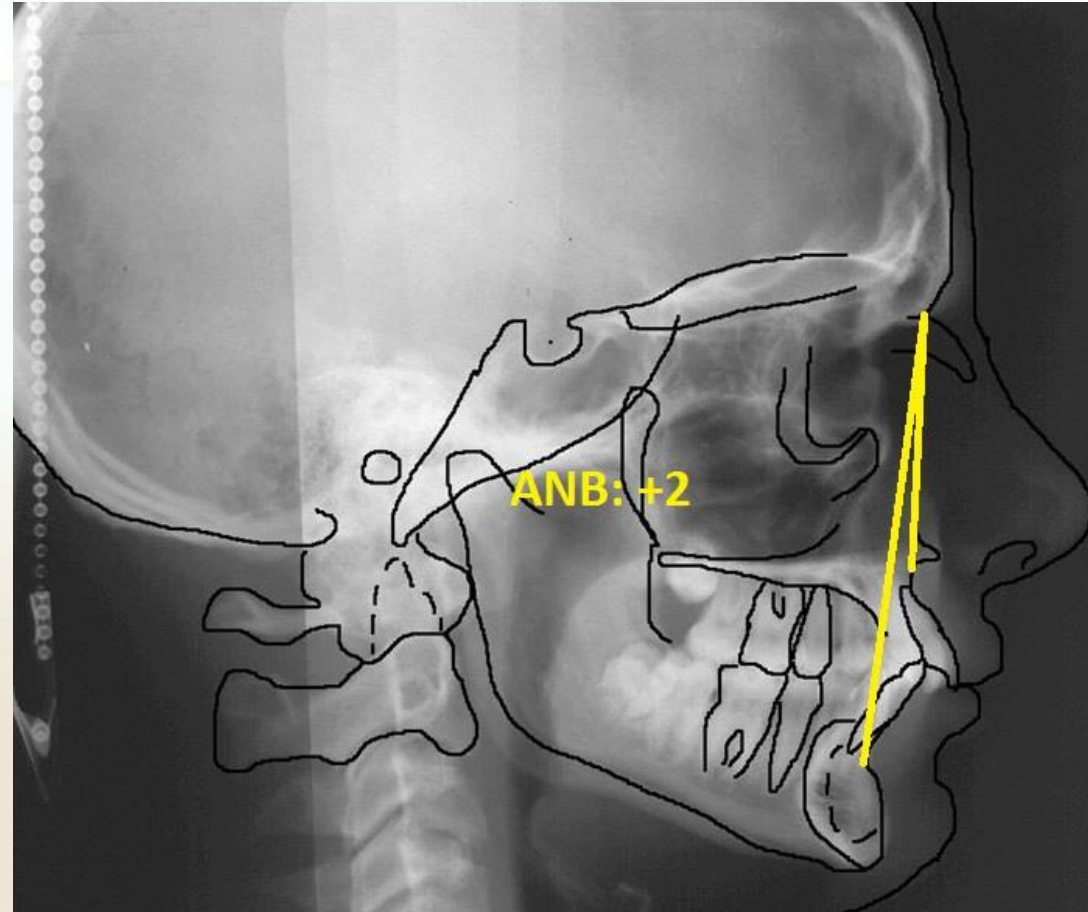


# Sagittal analysis skeletal horizontal mandible

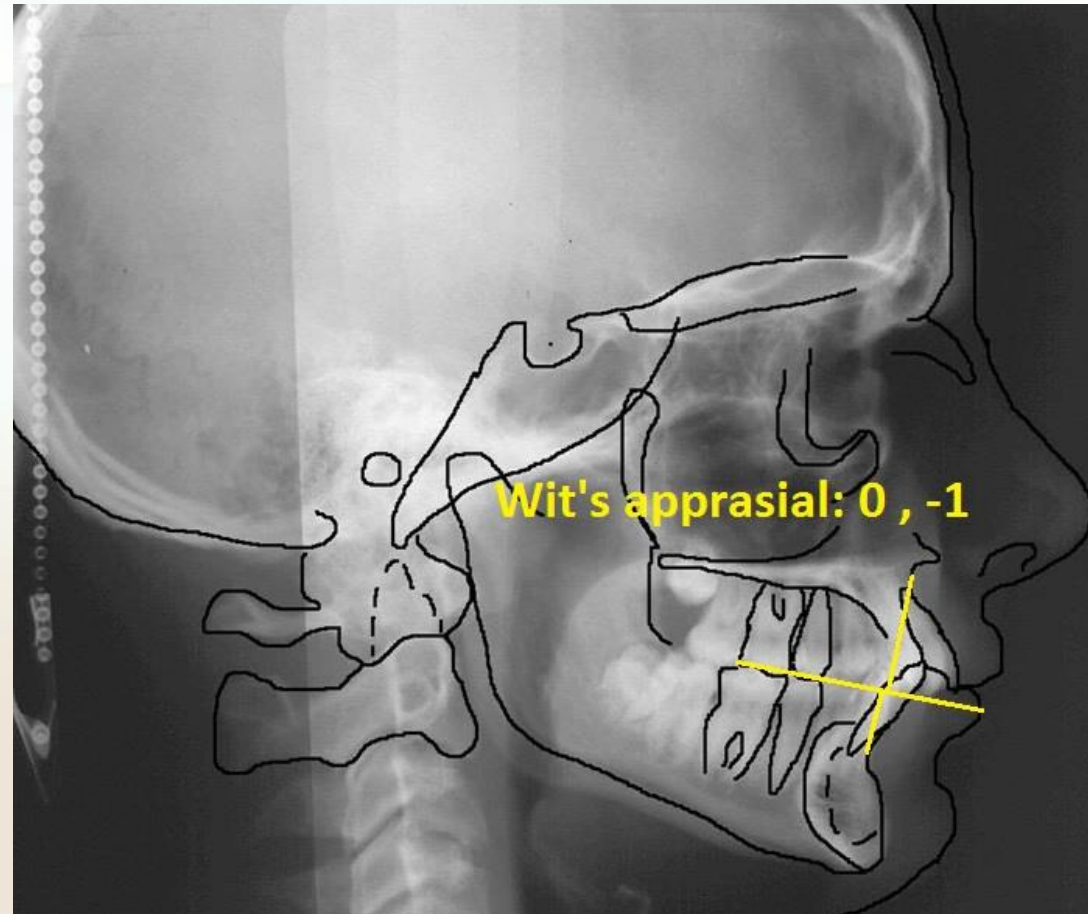




# Sagittal analysis – maxilla to mandible

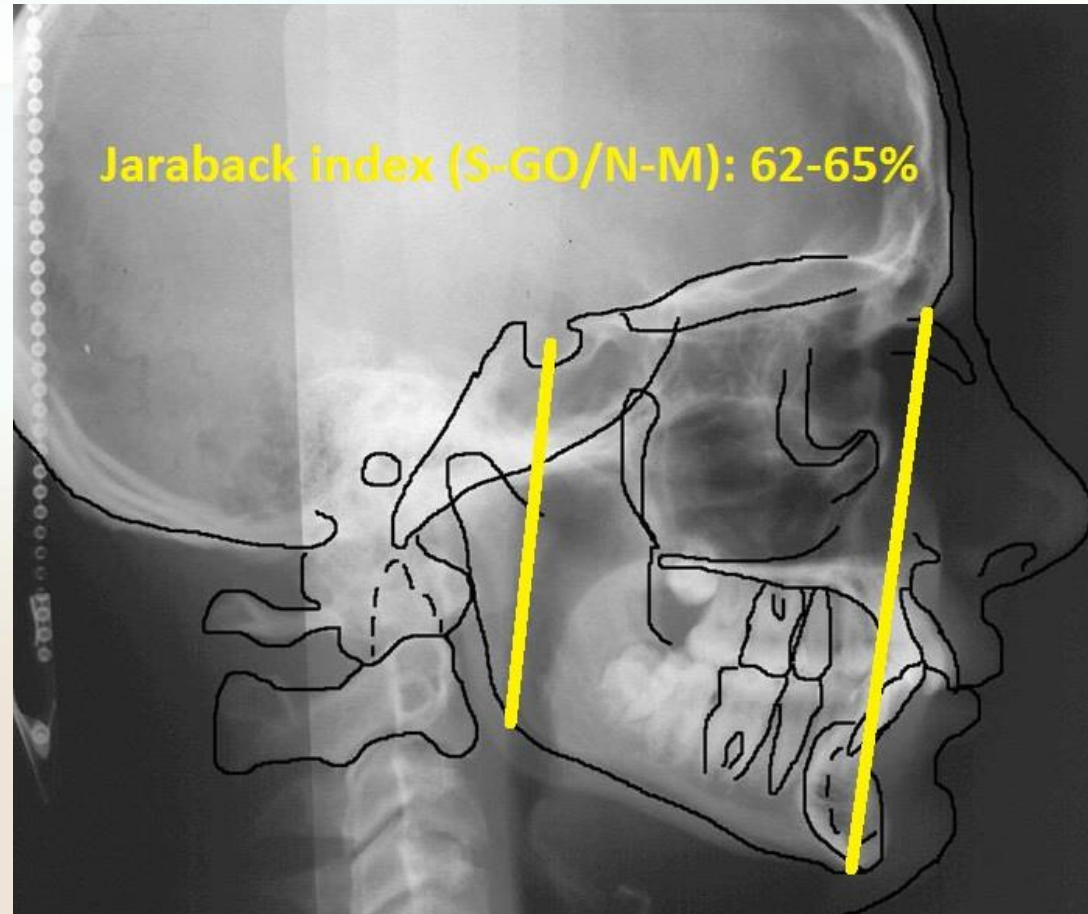


# Sagittal analysis – maxilla to mandible

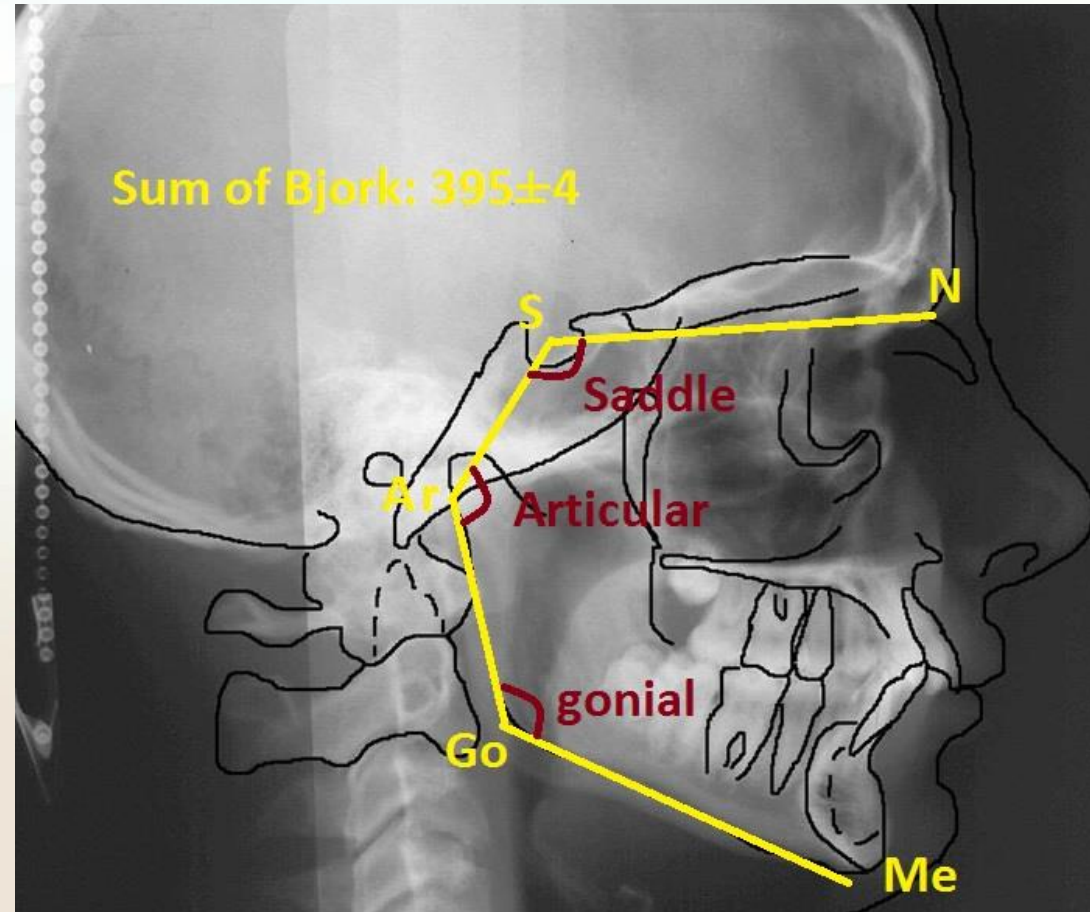


# Vertical analysis

# Vertical analysis – Growth pattern

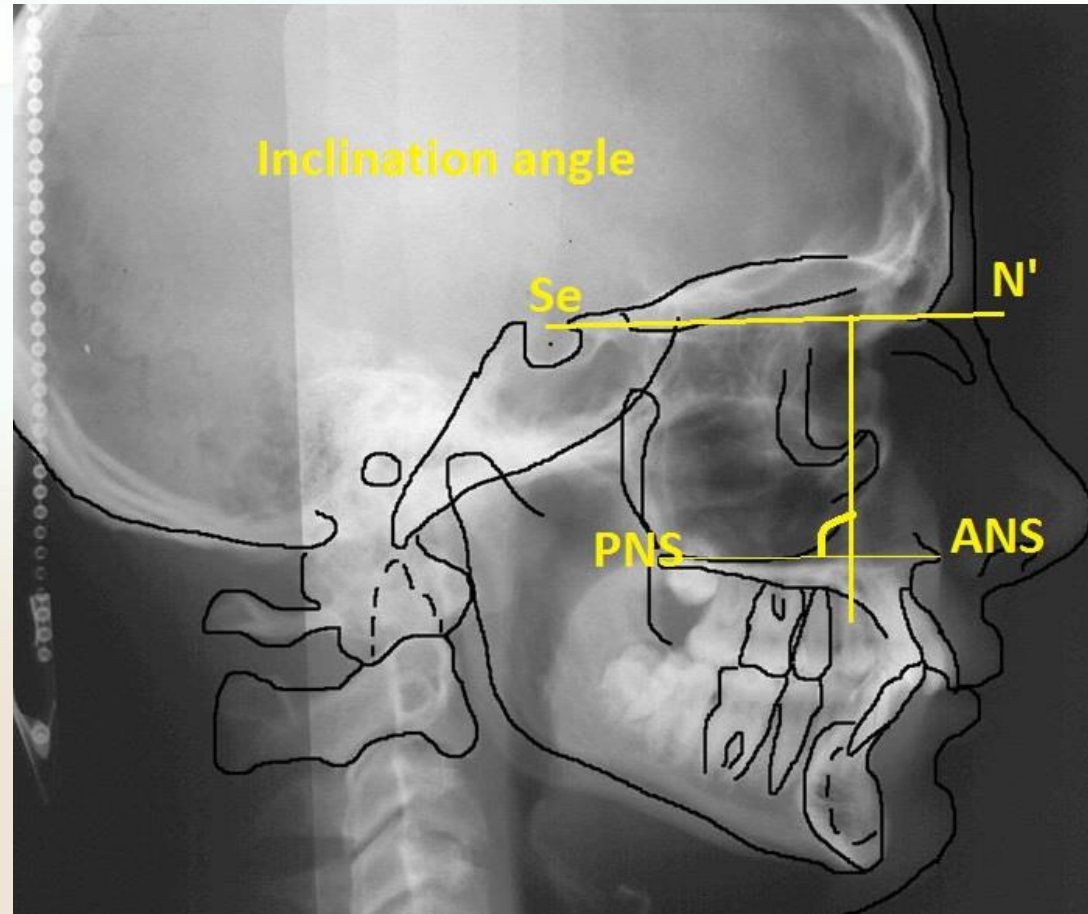


# Vertical analysis – Growth pattern

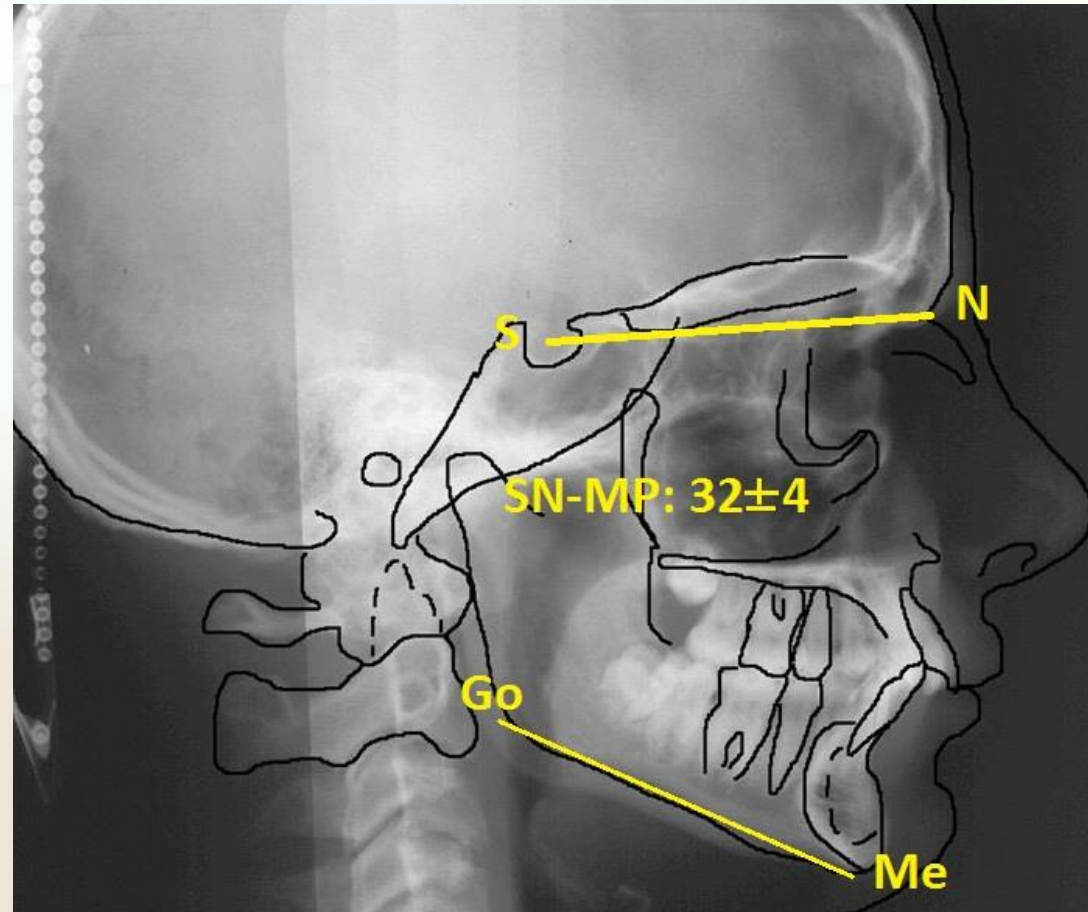




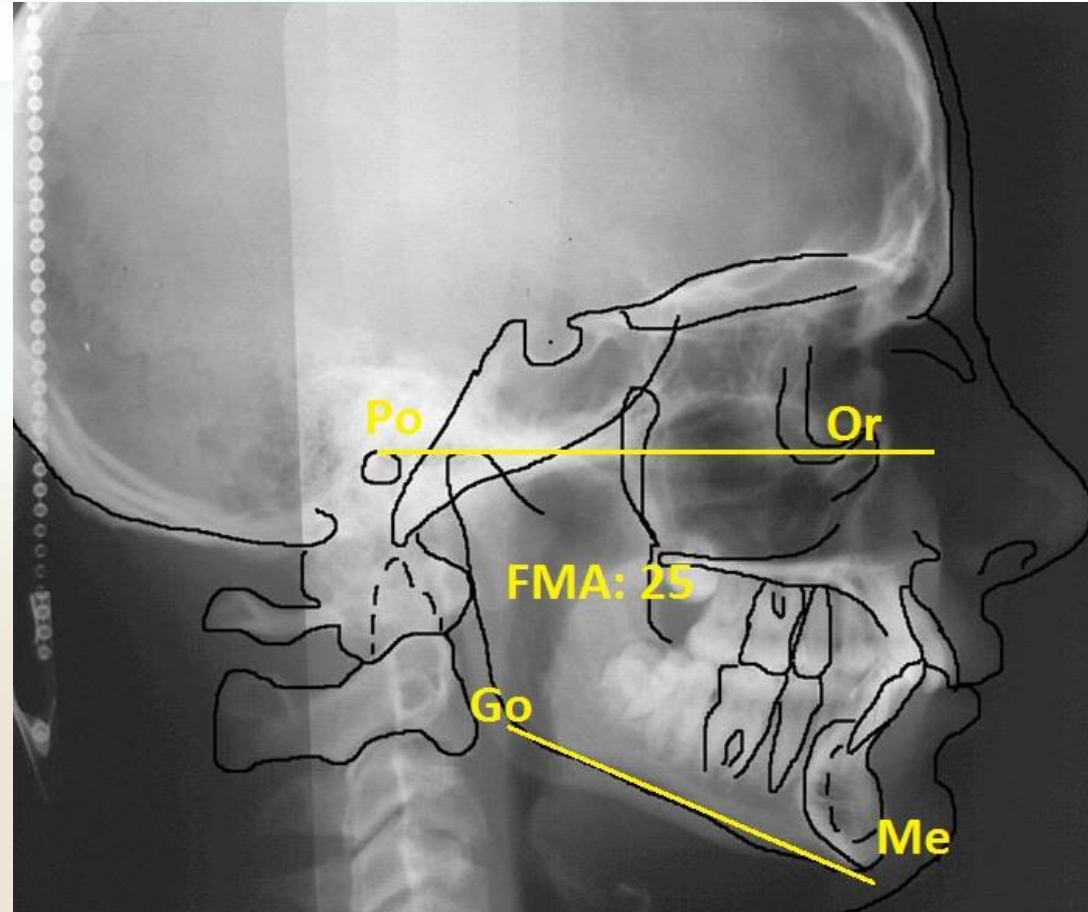
# Vertical analysis – Maxillary rotation



# Vertical analysis – Mandibular rotation

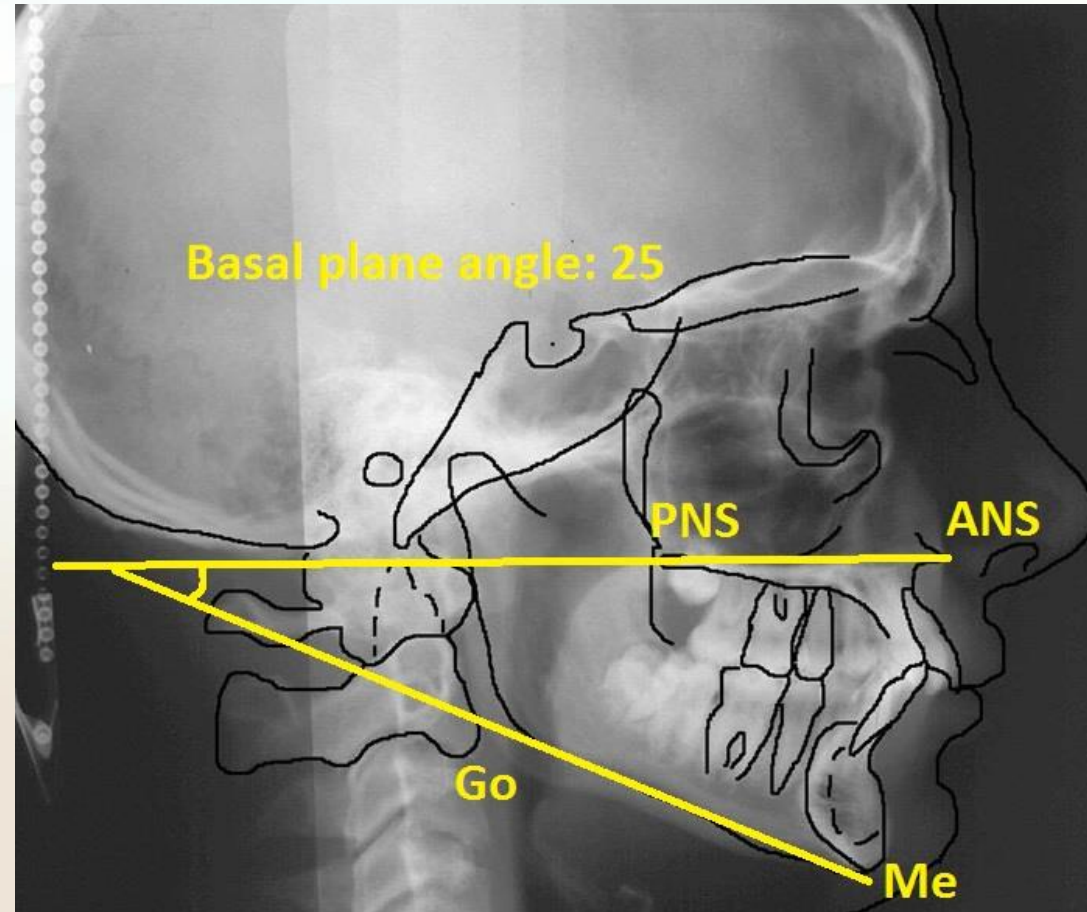


# Vertical analysis – Mandibular rotation

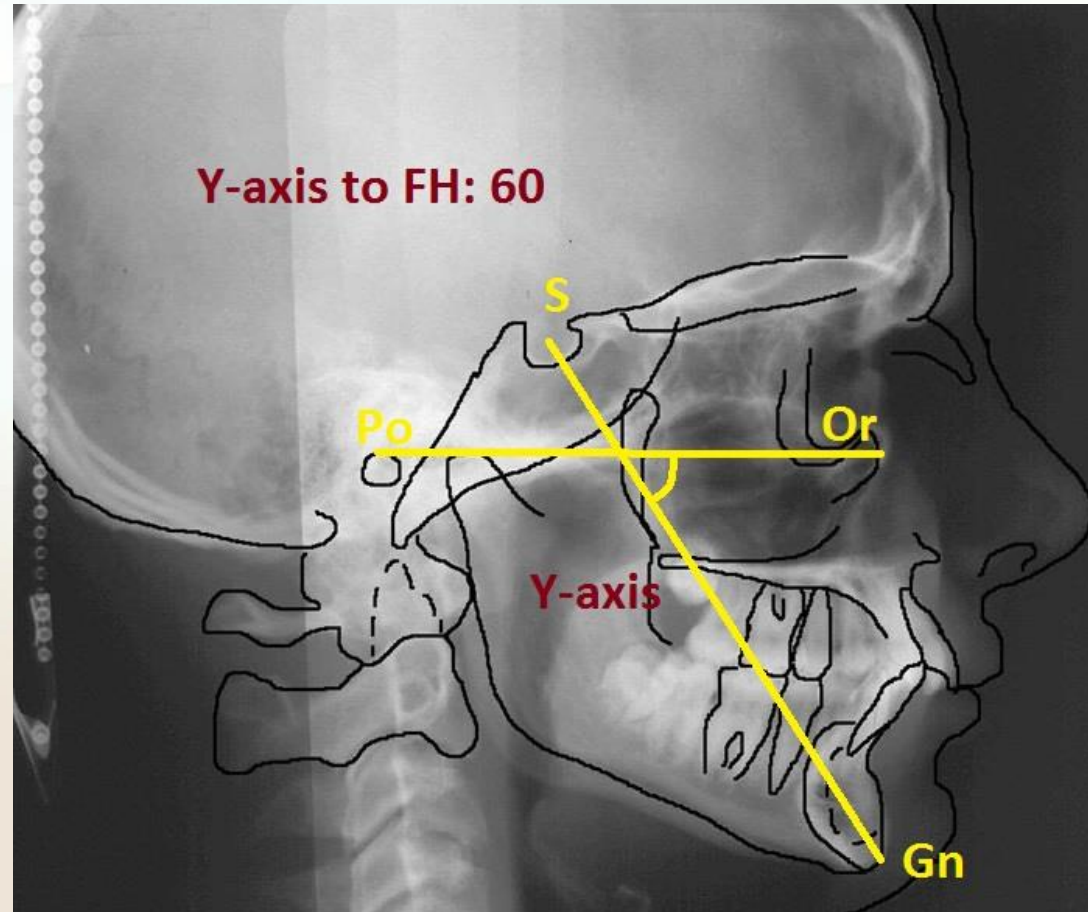




# Vertical analysis – Maxillomandibular relation

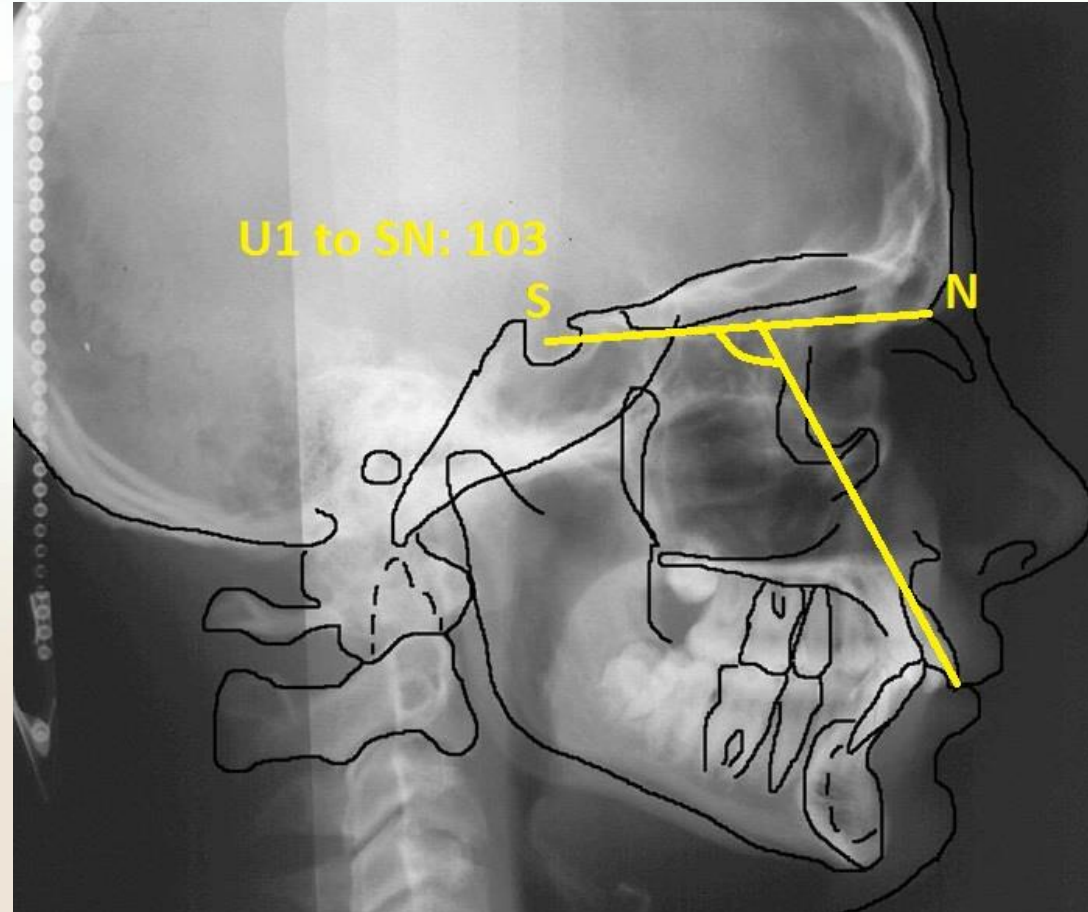


# Vertical analysis (Y-axis)

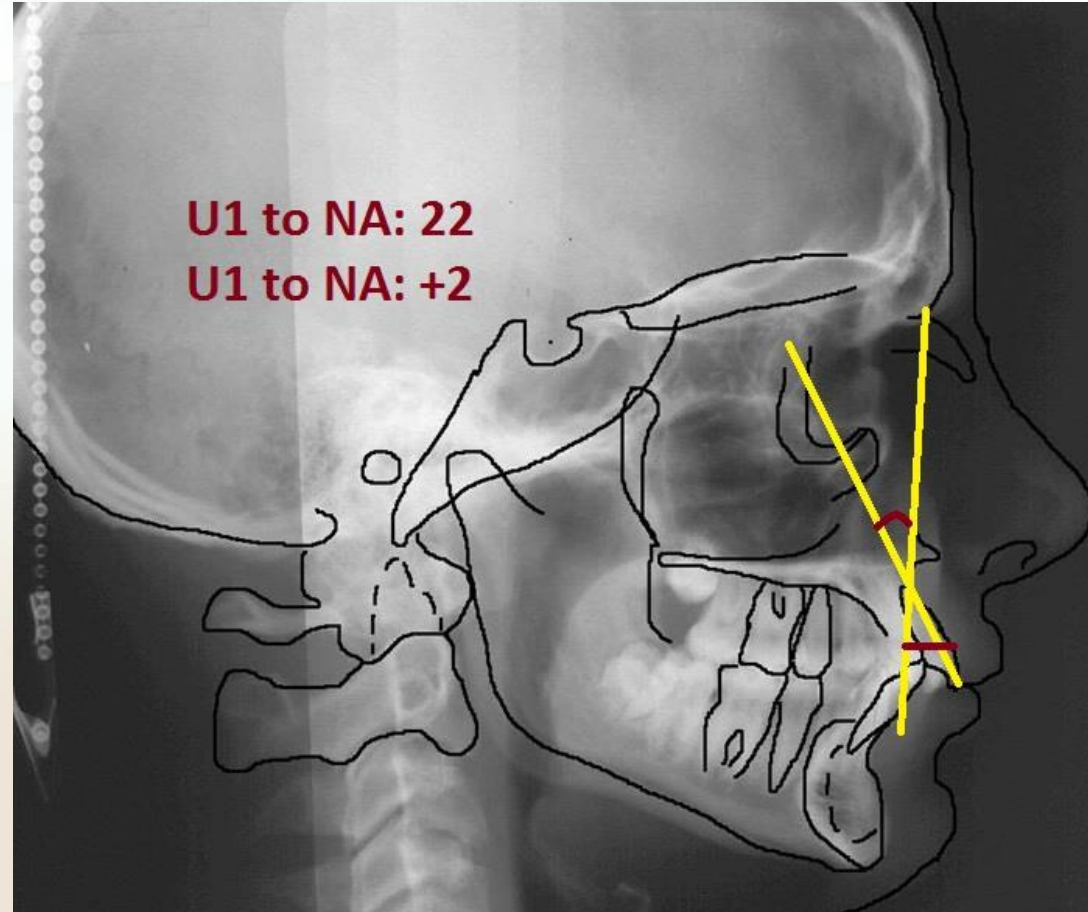


# Dental analysis

# Dental analysis – Upper incisor inclination

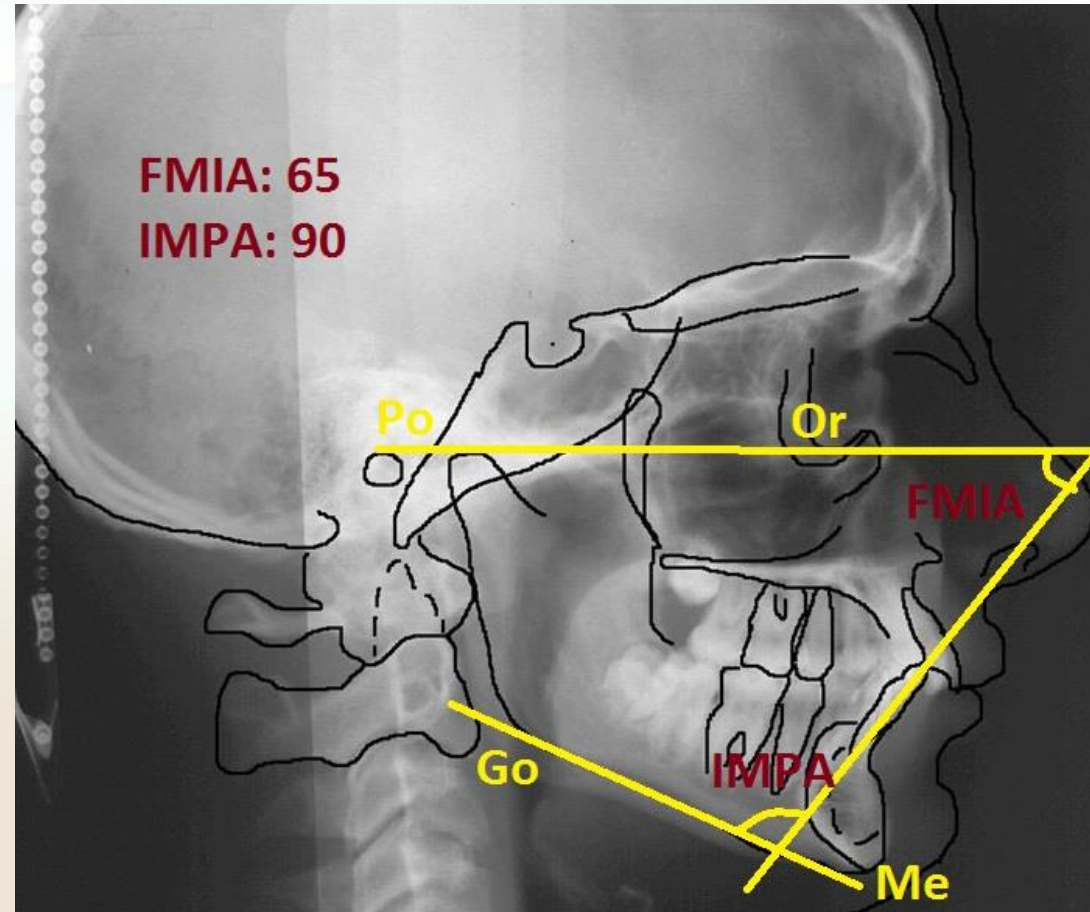


# Dental analysis – Upper incisor inclination

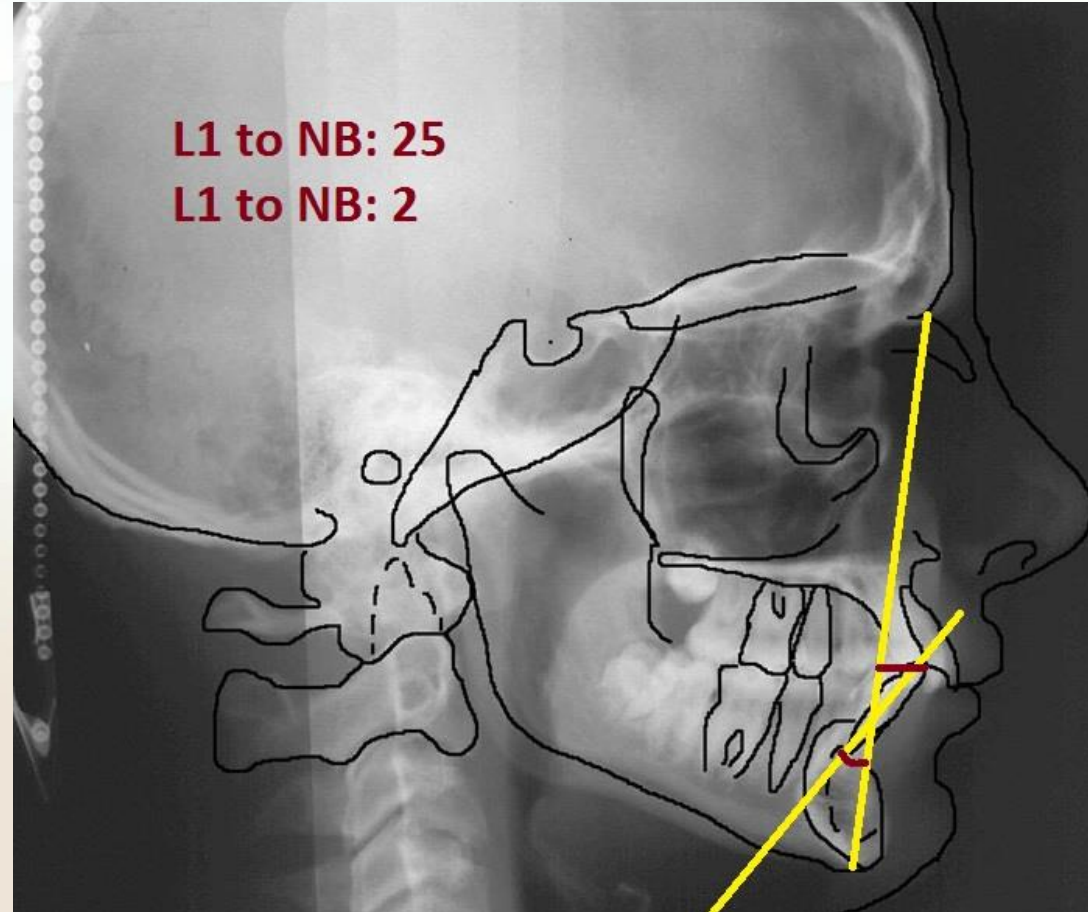




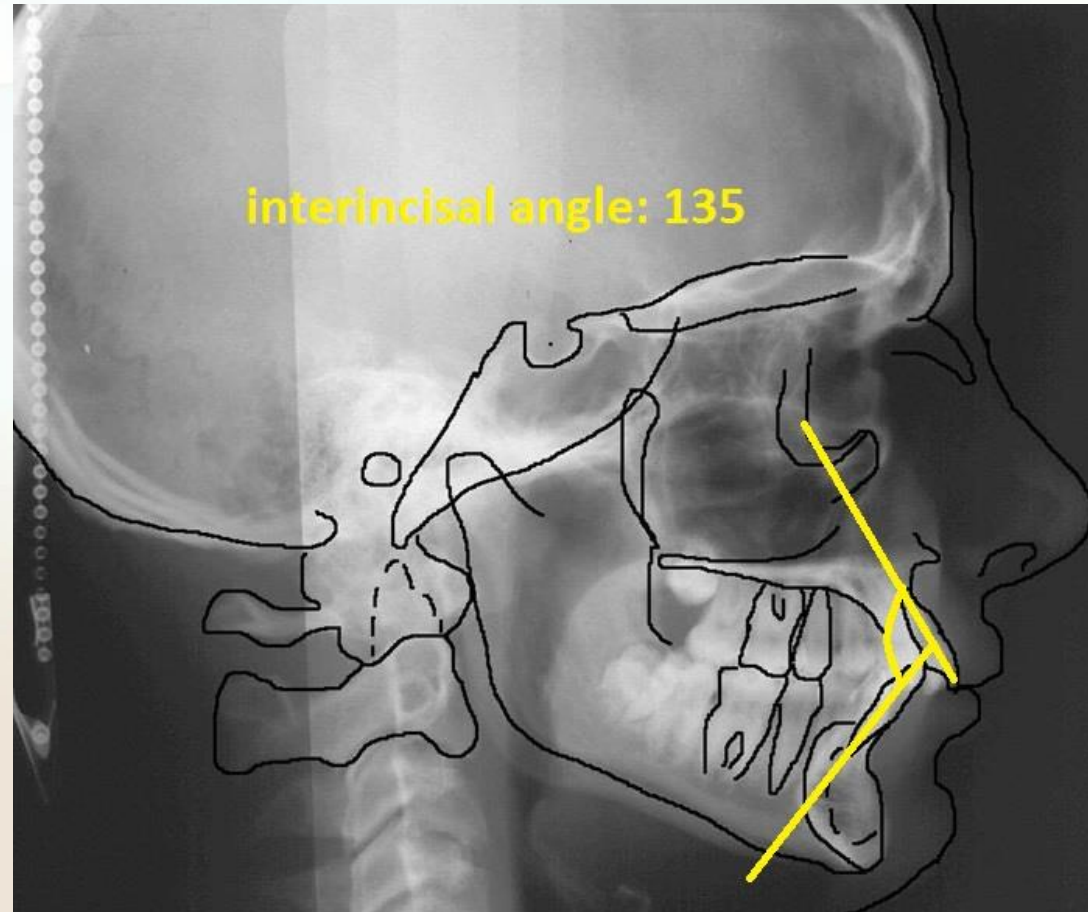
# Dental analysis – lower incisor inclination



# Dental analysis – lower incisor inclination

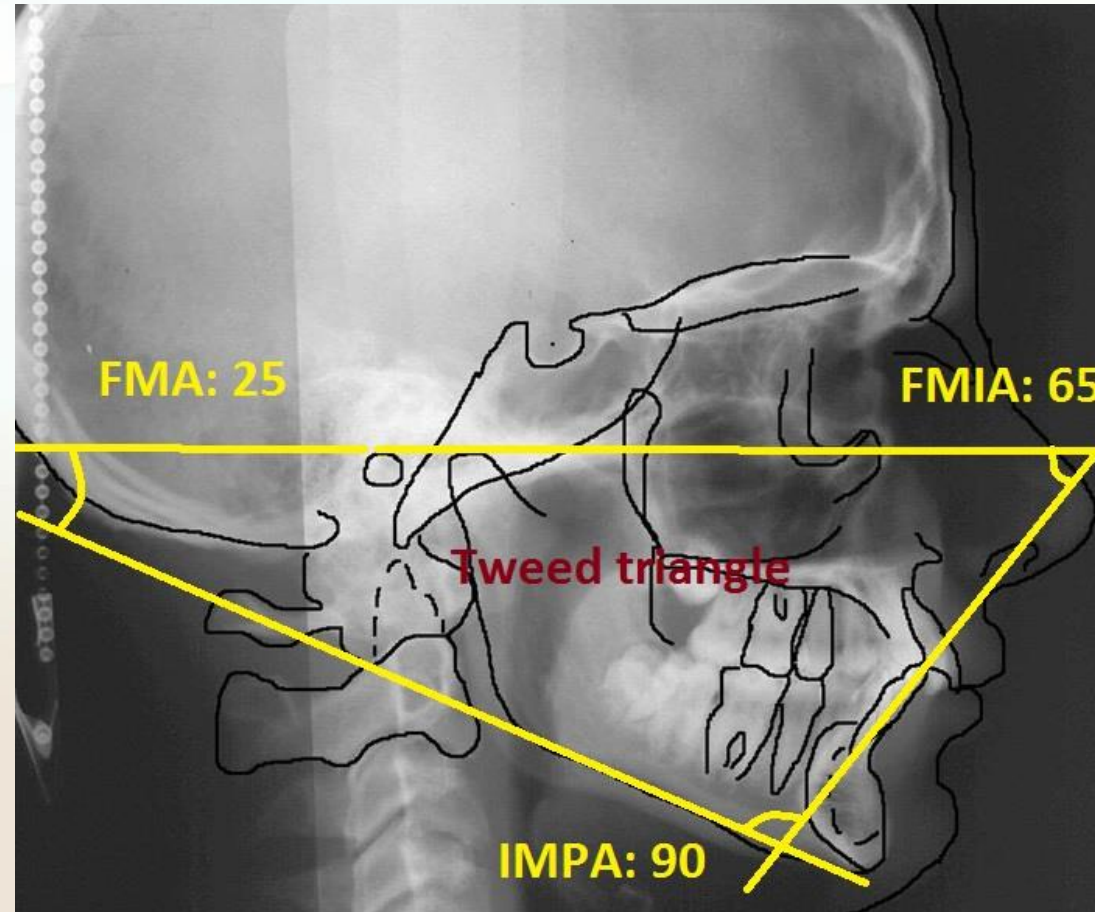


# Dental analysis – inter incisor relation



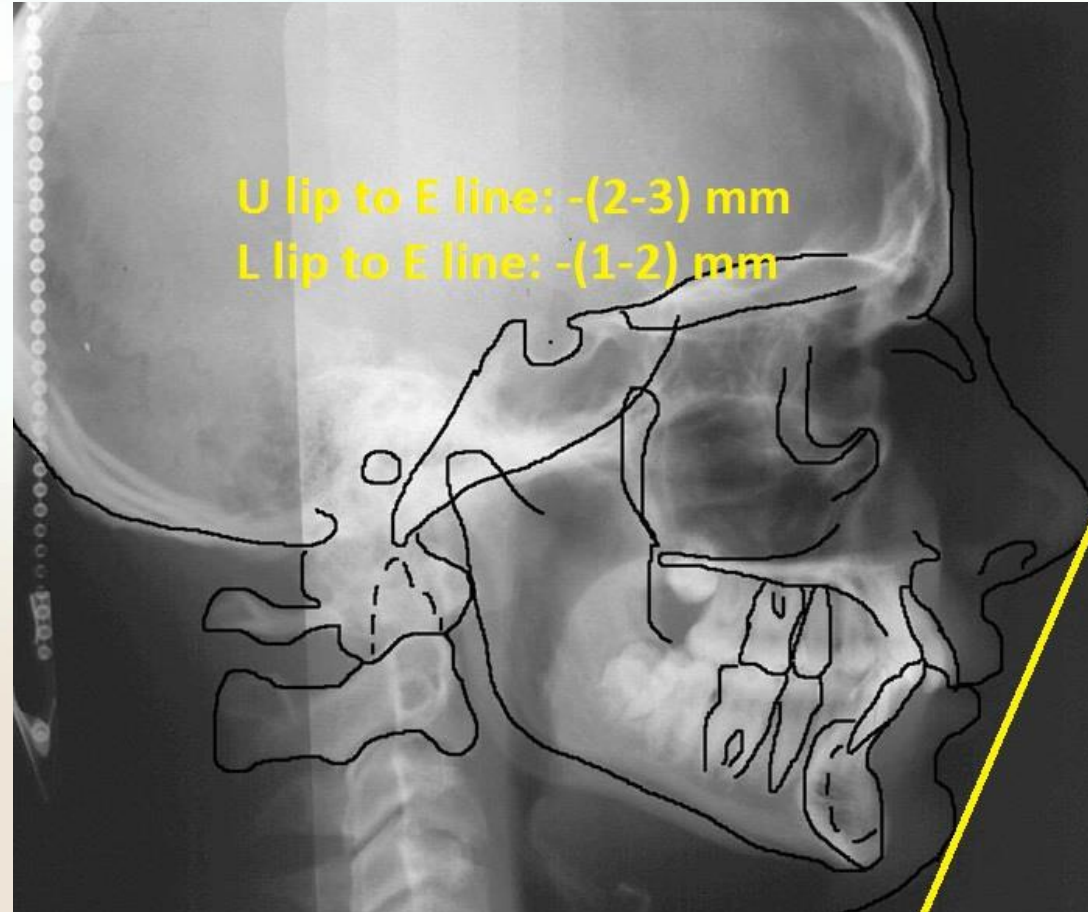


# Dental analysis - Tweed triangle

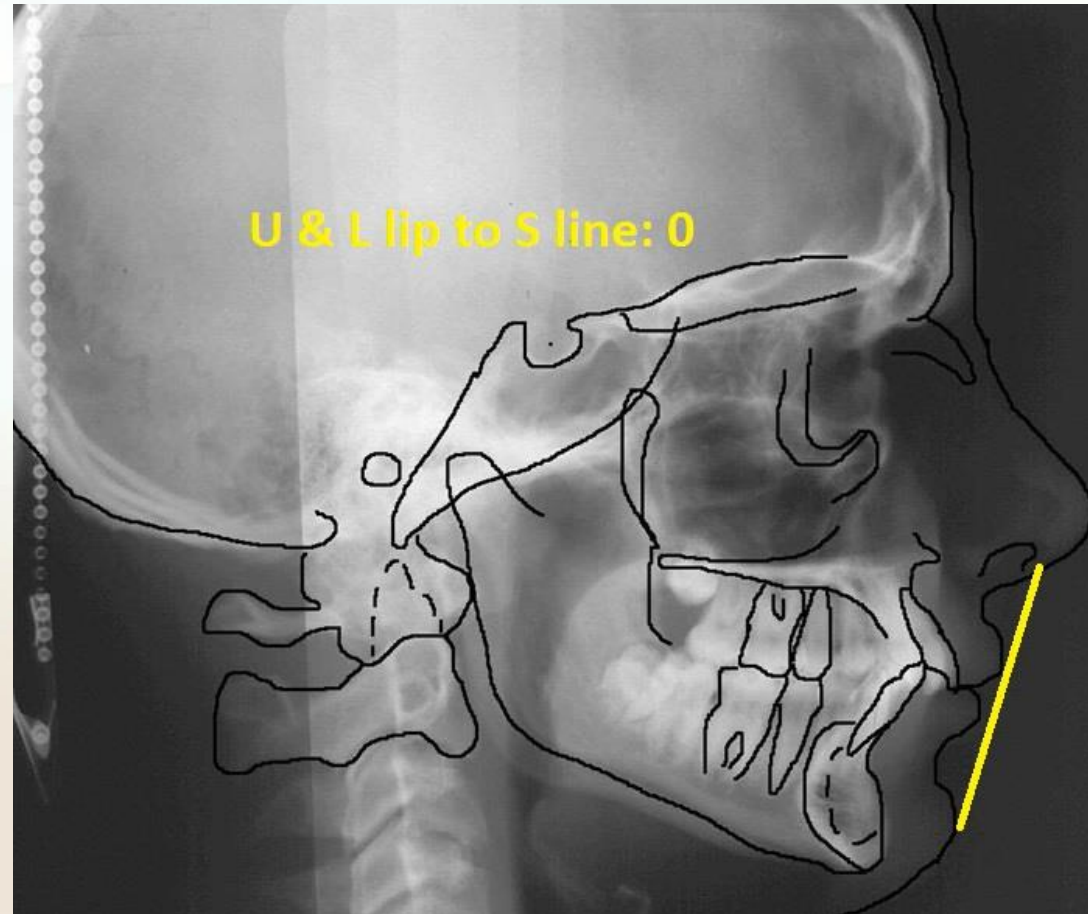


# Soft tissue analysis

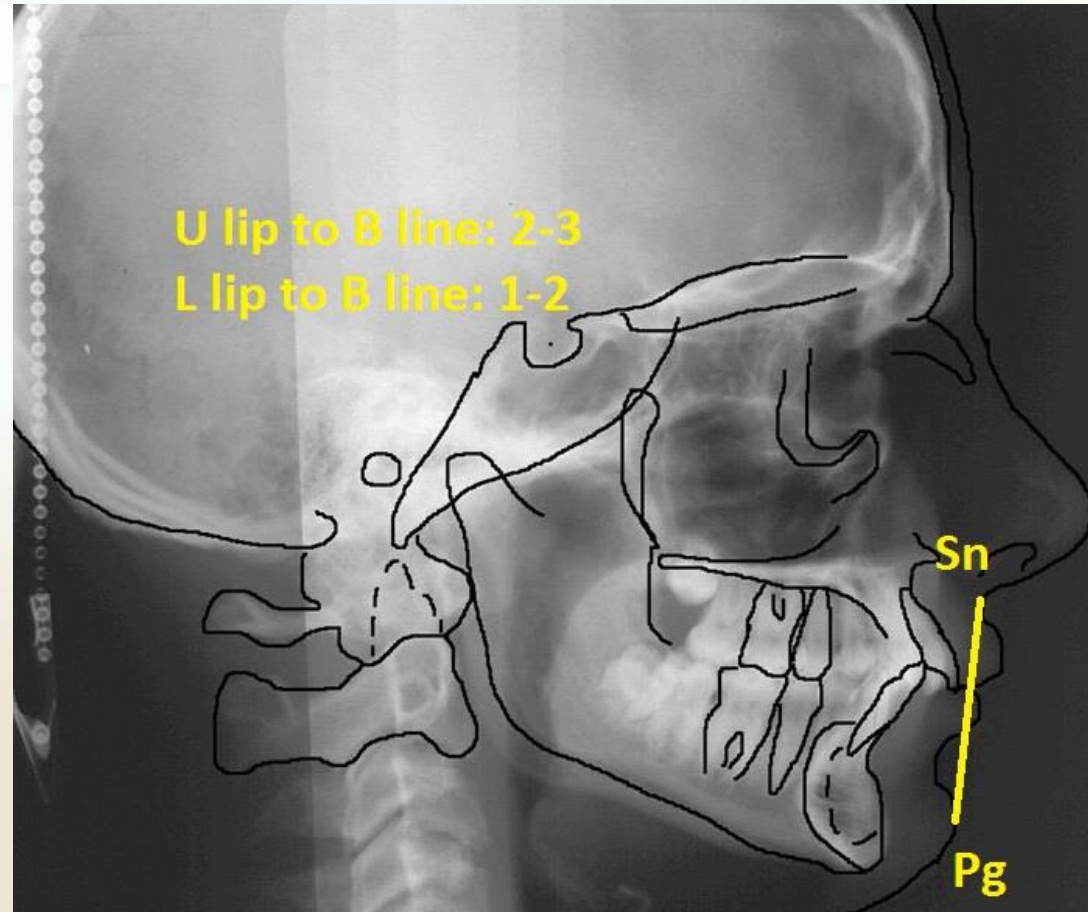
# Soft tissue analysis



# Soft tissue analysis



# Soft tissue analysis





SN-FH

# Summary

- As a complementary tool
- Relationship of dental, skeletal & soft tissue
- Numeric
- Superimposition
- Diagnosis, follow up

# References

- Diagnosis chapter of Proffit



خانه

ثبت اطلاعات بیماران

بیماران

دانشجویان و دستیاران تخصصی

تماس با ما

دکتر مریم کاراندیش

ورود به صفحه شخصی

راهنمای ورود به صفحه شخصی

کلاس مجازی

آموزشی

جزوه های کلاسهای تئوری

تکالیف دانشجویان گفتاردرمانی

THE HARMONY OF

ART & SCIENCE